

\$4.25

# PET QUARTERLY

Volume 5, Winter |



From your  
Veterinarian...



**CRACKING THE  
SECRETS OF TOOTH  
FRACTURES**

**PET DENTAL X-RAYS:  
THE PICTURE OF HEALTH**

**A PAINFUL,  
HIDDEN DISEASE  
IN CATS**

**PREVENTING  
PET DENTAL PROBLEMS**

**DANCING WITH  
THE DOGS**

**FRONTLINE® Plus is  
the vet's #1 choice  
in long-lasting  
flea protection.**



Say **goodbye** to  
fleas and ticks.™



FRONTLINE is a registered trademark, and  
"Say goodbye to fleas and ticks" is a trademark, of Merial.  
©2007 Merial Limited, Duluth, GA. All rights reserved.  
FLE-ADD-7-BUG

**Is your dog trying to  
tell you something?**

Ask your vet about FRONTLINE Plus,  
the one that's fast-acting, long-lasting  
and waterproof.



Say **goodbye** to fleas and ticks.™

# CONTENTS

Dental X-Rays for Pets / 2

Feline Stomatitis / 4

Fractured Teeth in Dogs and Cats / 6

Dancing with the Dogs / 8

Don't Brush off Dental Disease in Pets/ 10

Pet Dental Health Month / 12

**PETQUARTERLY**

winter, volume 5

**Pet Quarterly® is an educational resource provided by your veterinary hospital. It is published by Educational Concepts, LLC, Tulsa, Oklahoma.**

**Comments are welcome at [info@petquarterly.com](mailto:info@petquarterly.com)**

©Copyright 2008.

All rights reserved.

Pet Quarterly® magazine does not make any representations as to opinions or facts as presented. Reproduction of contents in any form is prohibited without prior written permission of the publisher.

**POSTMASTER:**

Send address changes to *Pet Quarterly*, 4905 34th Street South, PO Box 363, St. Petersburg, FL 33711.

winter, volume 5 ♦ pet quarterly



**Buster**



**Max**



**Rajah**



**Minnie**

# Pet Quarterly

## PHOTO ALBUM

Share your best pet photographs with other *Pet Quarterly* readers. Just email your pictures to [Petquarterly@yahoo.com](mailto:Petquarterly@yahoo.com). We'll pick the best to publish each issue. Shown here are a few of the members of the *PQ* staff's menagerie.



## The Picture of Health

# DENTAL X-RAYS FOR PETS

By Jeanne Perrone, CVT

**People recognize that maintaining good oral health plays a role in our overall well-being and, just as with other organ systems, finding dental problems early can often mean slowing or even stopping progression of disease. The “gold standard” for humans is to have dental x-rays taken once a year.**

Veterinary professionals are realizing that the same is true for our pets. One study conducted on 115 cats and 226 dogs found that oral radiographs (the technical term for dental x-rays) detected unrecognized disease in 28% of dogs and 42% of cats; in animals with known tooth problems, additional information was revealed by dental x-rays in approximately half the cases. This is because x-rays allow the veterinarian to examine the bone and tooth-supporting structures in addition to the teeth themselves.

### The Tip of the Iceberg

Dental x-rays provide a picture of what is going on below the gumline, where most oral disease occurs (Figure 1). Below the gumline is the tooth's root. This houses the pulp chamber, which holds the blood vessels and nerves that serve each tooth. Around the root is a structure called the periodontal ligament. Like springs on a trampoline, the periodontal ligament attaches the tooth root to the tooth socket. On an x-ray, this ligament appears as a line running around the perimeter of the root.

### Preparation

Many veterinary clinics are adding more thorough oral exams to their twice-yearly physicals, sometimes including dental radiographs using either a standard x-ray unit or a dental x-ray machine similar to the type found in human dental offices. Because most animals

**A thorough physical examination, including a dental exam, is the first step in preventing oral disease in pets.**

will not lie still or tolerate holding a film in their mouths, general anesthesia is necessary when taking x-rays to protect the animal and to safeguard the handler from injury and from excessive exposure to radiation.

**Disease Detection**

Just as in humans, the accumulation of plaque (food debris and bacteria) on the teeth leads to the gums becoming red, swollen, and inflamed—a common condition known as gingivitis. Bad breath and red or bleeding gums are important signs, although the animal might drop food and rub its mouth as well. Your veterinarian can reverse the damage with a proper dental cleaning but unchecked oral disease will wreak havoc, allowing toxins and bacteria to circulate and harm organs throughout the body.

Diseases of the pulp usually occur following trauma to the tooth. The crown, or top of the tooth, may or may not be fractured, and it could be discolored a pink or gray. Periodontal (gum) disease can also cause problems with the pulp. As destructive bacteria travel down the length of the tooth, they can enter through the tip of the root, causing damage and death to the pulp tissue (Figure 2). An x-ray will show a wider pulp chamber when compared to neighboring teeth or the same tooth on the opposite side, providing further information as to the extent of damage to the tooth.

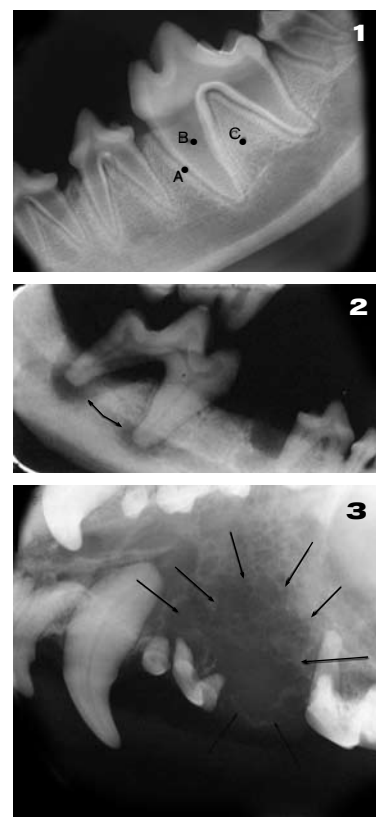
Abnormalities of the tooth socket and surrounding bone can be caused by disease in the gums or

tooth pulp, or sometimes by an oral tumor. Tumors, both malignant and benign, can locally invade the bone around teeth. On an x-ray, this will make the bone look moth-eaten and occasionally the teeth will have no attachment to the bone (Figure 3). X-rays will also give the veterinarian necessary information to determine the size of a tumor and whether bone is involved to help decide on the best course of action. Following treatment, follow-up x-rays are performed to make sure

**...unchecked oral disease will wreak havoc, allowing toxins and bacteria to circulate and harm organs throughout the body.**

the tumor has not returned.

Dental radiographs are fast becoming the dental standard for pet oral health. The information they provide allows the veterinarian to treat the patient more quickly and provide the patient a more comfortable mouth and the owner a happier pet. ■



**Figure 1.** A = lower first molar; B = pulp chamber; C = tooth socket  
**Figure 2.** Lower first molar. Note the bone destruction moving up into the pulp chamber.  
**Figure 3.** Upper jaw of a cat with a malignant oral tumor. Note the loss of bone from destruction caused by the tumor.

**American Veterinary Dental Society Recommendations for Reducing the Risk of Oral Disease**

- The first step: routine physical examination for pets, including a dental exam.
- Pet owners should practice a regular dental care regimen at home, which may include brushing the pet's teeth with specially formulated toothpaste. It's best to start early, but grown dogs and cats can learn to tolerate brushing. Toothpaste for humans is not recommended because it may upset the pet's stomach.
- Schedule regular follow-up care with your family veterinarian and ask about specially formulated foods with proven benefits in plaque and tartar removal.

# Oral Agony

## FELINE STOMATITIS

By Brett Beckman, DVM, FAVD, DAVDC, DAAPM

**Feline stomatitis is a very painful disease that affects the gums and/or the back portion of the mouth in cats. While eating might be causing a cat agony, many show no symptoms that their owners are able to recognize. Due to the painful nature of the disease, all cats should have regular oral examinations by a veterinarian to ensure that stomatitis is not present.**

### Cause and Symptoms

The cause of stomatitis is unknown but we do know the condition is related to the pet's immune system overreacting to something present in, on, or adjacent to, gum tissue. An antigen or protein causes the immune system to attack the gum tissue, creating a severe reaction in the gum and/or back portion of the oral cavity (**Figures 1 and 2**). Bacteria and viruses are suspected as causes.

Other than oral cancer, stomatitis is the most serious disease of the mouth. Symptoms vary (see

**Due to the painful nature of the disease, all cats should have regular oral examinations by a veterinarian to ensure that stomatitis is not present.**

**Symptoms of Feline Stomatitis** box) and unfortunately, cats are notorious for not showing symptoms until they are extremely ill, hiding signs of even serious diseases that could be diagnosed with regular veterinary visits (see "Is Your Cat Really Sick?" Volume 4/Fall). Feline stomatitis is no exception.

### Treatments

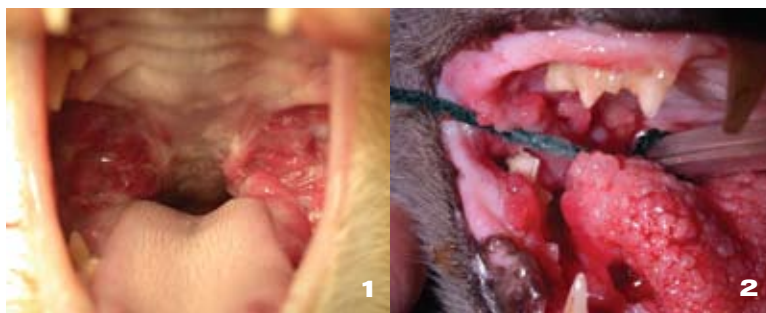
Historically, treatment for feline stomatitis has been unrewarding. Medical treatments can provide temporary relief of symptoms, but

until we understand what causes the condition, treatment is aimed at reducing tissue inflammation.

Steroid injections can help control inflammation, but they can cause serious side effects in cats and must be used sparingly and with caution. Steroid injections also become increasingly less effective over time. Antibiotics can help somewhat, but they also become less effective as time goes on. Laser treatment is sometimes used to provide a temporary positive benefit; but must be repeated every several months.

**Figure 1.** The back portion of the oral cavity behind the teeth is severely inflamed in this cat with stomatitis.

**Figure 2.** Severe stomatitis in a cat. It should be noted that cats experience pain well before this state is reached. Most cats do not have changes this severe.



### Double Trouble

Cats with stomatitis may have other diseases affecting the gums and/or the teeth in front of the mouth (canines and incisors) that also require care. A thorough oral examination, including an x-ray evaluation, may uncover periodontal disease or defects in the enamel known as *resorptive lesions*, which are troublesome because they are painful to the animal. Resorptive lesions are usually eliminated by extracting the affected teeth.

**It is extremely important that cats visit the veterinary office twice yearly for a thorough examination.**

### **Extract the Problem**

Currently, the only treatment that has proven to show significant results is extraction of the teeth in the back part of the mouth (molars and premolars). Most cats that have had extractions require no further treatment. Soft food is prescribed for two weeks. After this time some cats prefer to return to their dry kibble. For the remaining cats, some form of medical therapy is needed. A small number of cats do not improve regardless of the type of treatment.

### **Pain Control**

Pain management is particularly important before and after treatment. New understanding of different ways that the cat's body maintains pain allows your veterinarian to use combination of pain medications before and following surgery that provide much more effective pain relief for your cat than was possible in the past. This generally requires intravenous and injectable administration of pain medication for 24 hours before extractions are done, but helps avoid extended hospital stays and feeding tubes that were required in the past. Many cats eat very well a few hours after surgery even if they had poor appetites beforehand.

### **Difficult Disease**

Feline stomatitis is painful and serious. Symptoms may be vague or absent in some cats. Therefore,



## **Symptoms of Feline Stomatitis**

All cats do not show signs that they have this painful condition so twice-yearly check ups are important, but contact your veterinarian if your cat has any of the following symptoms.

- Halitosis (bad breath)
- Red gums
- Difficulty swallowing
- Lack of appetite
- Lethargy
- Blood-tinged saliva
- Difficulty holding onto food
- Abnormal tongue movements
- Tooth-grinding
- Poorly kept coat due to lack of self-grooming

it is extremely important that cats visit the veterinary office twice yearly for a thorough examination. The mouth should receive special attention due to the severe consequences of this disease in our feline companions. ■

**Understanding the different ways that the cat's body maintains pain allows us to choose medications to combat the entire pain response.**



# Fractured Teeth IN DOGS AND CATS

By Sharon Hoffman, DVM, DAVDC

**If you fractured your tooth today, you would not be reading this article—you would be at the emergency room or your dentist's office seeking relief. Fractured teeth in dogs and cats are not much different than fractured teeth in people.**

Although shaped differently, our pets' teeth are similar to ours and the pain an animal experiences after fracturing a tooth is similar, too. Our pets, however, can't tell us how much they hurt; they continue to eat, play, and work. Fortunately, fractured teeth can be treated and in many cases fractures can be prevented.

## What Causes Tooth Fractures?

Inappropriate chewing behavior in dogs, or accidents in dogs and cats, can fracture teeth (**Figure 1**). Several popular items purchased for dogs to chew are known to fracture teeth, including meat bones (soup bones or knuckle bones, for example), nylon bones, cattle hooves, and some pressed rawhide chews. Toys such as Frisbees and balls can lead to fractured teeth if they are thrown on hard surfaces like concrete. Dogs that chew rocks also risk tooth fractures. Firm rubber toys that are bendable (eg, Kong toys; [www.kongcompany.com](http://www.kongcompany.com)) are recommended instead of harder chews.

### Problem Behaviors

Two particular behaviors predispose dogs to tooth fractures: cage chewing and separation anxiety. The dog that chews its cage or fence gradually wears away the back surface of its canine ("eye") teeth, causing them to

become thin and weak (**Figure 2**) and at high risk of fracture with continued cage chewing. A dog that has separation anxiety may engage in destructive chewing

**Be sure to consult with your veterinarian if your dog engages in cage chewing or exhibits separation anxiety.**

when separated from its owner and might fracture a tooth with the owner being none the wiser.

Both these common behavior problems can be treated through behavior modification. Be sure to consult with your veterinarian if your dog engages in cage chewing or exhibits separation anxiety.

### What Cues Should I Watch for?

Remember, a pet will not usually let you know it is in pain with a fractured tooth. Your dog or cat may adapt by chewing food on one side of the mouth more than the other, or you may notice your dog does not want to

#### HEADS UP:

See the important information from your veterinarian on the front cover

## A veterinarian should perform a dental examination as part of a twice-yearly check up.

chew on its toys. In most cases, however, the pet owner will not notice any behavior change.

It is important to look at the pet's teeth regularly by gently lifting the lip while the mouth is closed. Check to see if the canine teeth are the same length on both sides. If you are able to see the back teeth, they should look the same on both sides as well. Your veterinary staff can help you learn to examine your pet's teeth safely and comfortably.

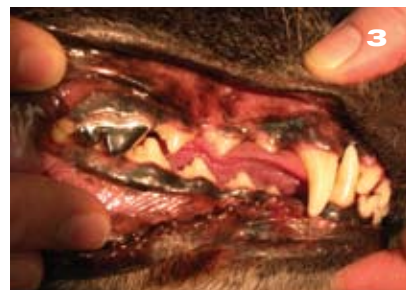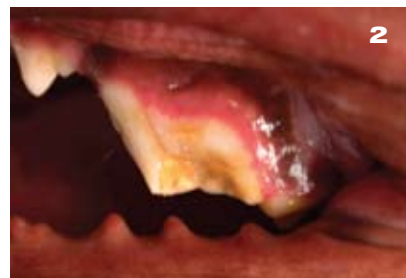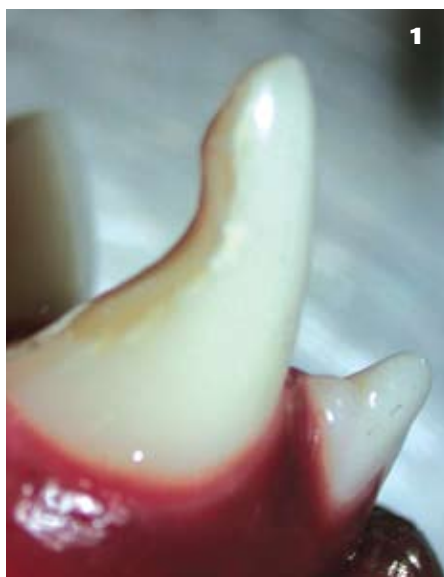A veterinarian should perform a dental examination as part of a twice-yearly check up, or more often if the animal has a history of inappropriate chewing behavior (Figure 3).

### How Does a Fractured Tooth Affect My Pet?

How a dog or cat is affected by a fractured tooth depends on several factors:

- Depth of the fracture
- Age of the fracture
- Age of the tooth

For instance, when the enamel is fractured, the dentin—the main part of a tooth beneath the enamel and surrounding the pulp chamber and roots—becomes exposed. The dentin is porous or “leaky” and sets up the rest of the tooth for infection. A fracture into the enamel and dentin also weakens the tooth. The deepest fractures involve the enamel, dentin, and pulp. These are emergency situations. The pulp, the innermost part of each tooth, contains the blood and



**Figure 1.** This premolar is fractured. The most common cause of this type of fracture is chewing on bones, nylon bones, cattle hooves, or rocks. **Figure 2.** The back of this canine tooth has been damaged from cage chewing. It has begun to look hook-shaped instead of a normal cone shape. **Figure 3.** This picture demonstrates an oral exam of the teeth. The pet's mouth is closed and the lips are lifted. A premolar has been repaired with a metal crown after root canal therapy.

nerve supplies. If the tooth fracture involves the pulp, the pet experiences immediate and intense pain. Left untreated, the pulp dies within a few hours to days, and the intense pain subsides. However, infection continues to enter the pulp through the fracture site and eventually can lead to an abscessed root, a draining tract, infection of the jaw, and chronic, ongoing pain. Unlike a broken bone or an open wound, a fractured tooth can never heal or “seal over” and antibiotics cannot cure the infection.

### What Should I Do if My Pet Has Fractured a Tooth?

Fractured teeth with pulp exposure need immediate treatment, preferably within 48 hours. Primary teeth will need to be extracted to prevent permanent damage to the unerupted permanent tooth. Permanent teeth with pulp exposures can sometimes be treated with root canal therapy, in a way

## Your veterinary staff can help you learn to examine your pet's teeth safely and comfortably.

similar to people. This treatment allows the pet to keep the tooth. Metal crowns (caps) are also available after root canal treatment. X-rays will be needed to determine the damage to the root(s) of the tooth. If the tooth root is involved in much of the fracture, the tooth will need to be surgically extracted.

Treatment, either root canal therapy or extraction, should not be delayed. The “watch and wait” approach prolongs the pet's pain as infection and damage progress. It is important NOT to wait for drainage or swelling, which are signs of ongoing damage and continued pain. Preventing tooth fractures and treating fractures as soon as they are noticed is the best way to keep your pet pain-free. ■

# DANCING WITH THE DOGS

**Do holiday indulgences tend to linger on your waistline? Is your canine companion one of the 40% that the American Veterinary Medical Association classifies as overweight? This year, resolve to try a new activity that will benefit both you and your dog: canine freestyle dancing.**

“It’s the best fun you’ve ever had,” says Patie Ventre, founder of the World Canine Freestyle Organization. Based on basic obedience training, freestyle dancing adds dimensions such as music, timing, costuming, routine development, and showmanship. The object of musical freestyle is to display the dog and handler in a creative, innovative manner. “If you love music and you’ve always wanted to be on Broadway, this is the sport for you,” says Ventre.


Perhaps the best way to appreciate canine freestyle dancing is to see it. Videos from all over the world are available online (see **Box**), and while routines vary from dramatic skits to intricate dressage-like routines, the common elements are cooperation between dog and human and the team’s enjoyment of one another.

Any dog, regardless of size or breed, can be a dancer. Ventre explains, “Any breed can do well, it’s not a sport dominated by borders and goldens. A dog is a pack animal—it wants to please its owner. Training a dog to the highest level requires training in a positive manner, so in freestyle dancing the dog does what it loves to do with the person it loves best.

“Vets think it’s great for their patients,” she continues. “In musical freestyle, the dog is constantly working, heeling both on the right and the left, which evenly develops muscle groups. It’s good for dogs with hip problems and helps them keep active and limber.” The owner gets a workout, too. “My dog Dancer and I do a 3-minute fast mambo and by the end of the



Courtesy Diane Kowalski



Courtesy Diane Kowalski

**Above.** Diane Kowalski and her partner Jazz.

routine, I'm exhausted. It's not like obedience competition where the owner is standing still and the dog is doing all the work" Ventre laughs.

## Get Up and Dance

Are you ready to cha cha with your chow-chow or polka with your pit bull? It's easy to get started. "Go on your computer and do some research," Ventre advises. "Training videos and books are available to learn the basic commands and strategies. "Find a club in your area, and link up with some people who might be able to tell you where to see an event or recommend videos, instruction books, and give advice on your specific dog's breed.

"When you start training your dog, you will develop a nice bond, a very positive relationship. With some time and effort you will see the 'light bulb' go off in the dog's head as he understands what you want him to do," she says.

"As you progress in training, you will probably want to take a training workshop. Eventually, you might want to compete," Ventre comments. There are categories for every type of competitor from beginner to expert; 4-H youngsters to "Sassy Seniors"—dogs over age 9 and/or owners over 65. Even animals or owners with disabilities such as blindness, deafness, or amputations are able to compete in freestyling. "We have people compete in wheelchairs," she says.

While the judging is serious, evaluating heel work, jumping, distance covered, expression, and other criteria, Ventre says event days are like parties. "Our theme



**Top, left.** Patie Ventre and Dancer perform their "God Bless America" tribute.



**Top, right.** Una Valanski and Spenser sharing a kiss after a great routine.

is sharing and bonding. Today's champion can be tomorrow's last place. New competitors are immediately brought into the fold; it's a warm and friendly sport that the whole family can come out and enjoy."

## Video Competition

Canine freestyling offers another unique option in sports: video competitions that allow teams to enter regardless of the physical or financial ability to travel. Video competitions also circumvent quarantine regulations that govern travel with animals. "This way, people can compete from all over the world," Ventre notes.

## Olympic Dreams

The World Canine Freestyle Organization based in Brooklyn, New York, is a nonprofit corporation with club branches across the United States and around the world. "Our newest club, the Melbourne Canine Freestylers just started up in Australia," Ventre says. Dog dancing is more than a hobby with Ventre, it's a mission. "My goal is to make freestyle dancing an Olympic sport, just like ballroom dancing or pairs skating. It's a true team sport—the only difference is that one of the team members happens to be a dog." ■

## Canine Freestyle Dancing

Check these organizations' Web sites for instructional videos, training information, competition rules and categories, dates, regional club contacts, FAQs, and contacts.

**World Canine Freestyle Organization**

[www.worldcaninefreestyle.org](http://www.worldcaninefreestyle.org)

**Musical Dog Sport Association**

[www.musicaldogsport.org](http://www.musicaldogsport.org)

**Canine Freestyle Federation, Inc.**

[www.canine-freestyle.org](http://www.canine-freestyle.org)

# Don't Brush off DENTAL DISEASE IN PETS

By R. Michael Peak, DVM, DAVDC

**Over the past 20+ years, veterinarians and pet owners alike have begun to recognize the importance of dental health. As our four-legged friends have moved from the backyard to the bedroom, we are focusing more on preventive medicine and enhancing their overall well-being. An important component of this is maintaining pets' dental health.**

## Healthy Teeth, Healthy Pet

There is mounting evidence in both veterinary and human medical literature to support a link between the health of teeth and gums with overall health. There are local (meaning just around the teeth) as well as systemic (affecting other organs of the body) effects of dental disease, some of which may be more significant than we know. The bottom line: if optimum health is the goal for our pets, we should take dental disease seriously. The problem is that much of dental disease is hidden below the gum line and typically is a slow, insidious process without obvious damaging effects.

Periodontal disease has been estimated to be the most common disease process in our pets. Many other dental diseases, such as broken teeth, painful cavities lesions, discolored teeth, root

fractures, and oral tumors are slowly progressive and most pets show few signs of a problem. In most instances, pets can have abscessed teeth, continue to eat, don't show any swelling or drainage of pus, and certainly don't say "my tooth hurts." It is up to owners to be aware of the possibility of dental disease and look closely for any of its signs.

## Read the Signs

Look for halitosis (bad breath), gingivitis (red gums), swollen gums, or broken or discolored teeth. Any of these could be signs of significant dental disease and should be pointed out to your veterinarian.

These conditions can set up a tooth, or many teeth, for a chronic (long-term) infection. With dental infections, pets usually don't run a fever, stop eating, or give any other indication they are ill. The problem is the constant infection from the plaque bacteria—and the

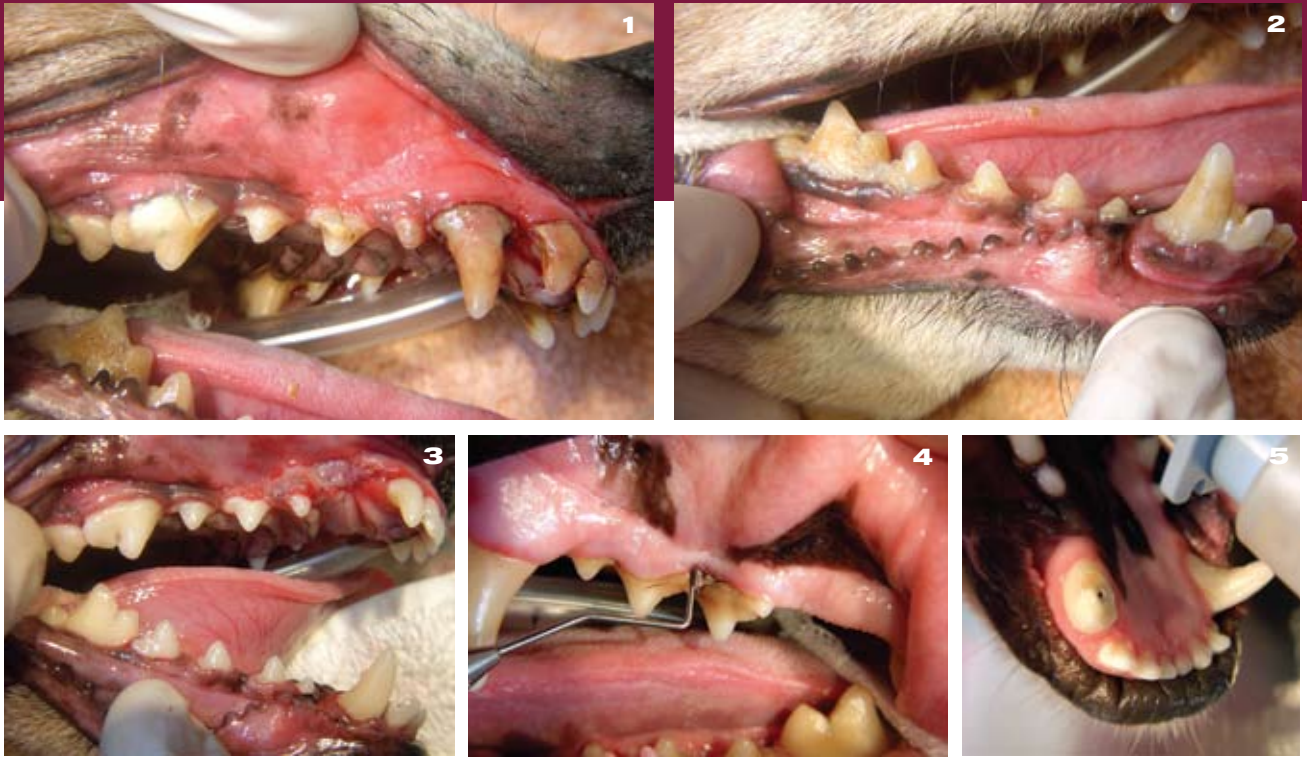breakdown products from these bacteria—into the surrounding tissues and bloodstream. The pet's immune response is a help, but also contributes to the inflammation by releasing chemicals that signal other immune cells to the area, almost like sounding an alarm to the rest of the body that there is a fire that needs to be put out. These inflammatory cells cause further tissue breakdown and also release chemicals that may be damaging to other organs in a long-term situation.

## Infection Tied to Disease?

In human and veterinary dentistry, associations have been made between these long-standing, low-level infections, and the development of disease in other organs. Studies in veterinary medicine have shown an association between advanced periodontal disease and microscopic changes within the

## Points to Remember

- Mounting evidence in veterinary medicine suggests a link between the health of teeth and gums and overall health of pets.
- Studies in veterinary medicine have shown an association between advanced periodontal disease and microscopic changes within the heart muscle, kidneys, and liver.
- Periodic cleaning and dental examination of your pet's teeth by your veterinarian are the best defense against long-standing dental disease.



**Figure 1.** This is the upper right jaw of a dog showing heavy plaque and calculus with swollen, red, and bleeding gums. Deep periodontal disease was found around the right upper canine tooth when examined with a periodontal probe. **Figure 2.** The same patient showing heavy plaque and tartar of the right lower jaw teeth. To keep these teeth healthy and prevent chronic infection, these teeth need to be cleaned professionally and maintained with home hygiene. **Figure 3.** These are the same teeth as above following removal of the diseased canine tooth, cleaning, polishing and periodontal therapy. **Figure 4.** Periodontal probing is essential to find the disease hiding below the gumline. **Figure 5.** This broken tooth has a pulp canal exposure and is a source of chronic infection. Teeth should be treated with either extraction or root canal therapy.

heart muscle, kidneys, and liver. It is important to point out that it remains to be proven whether dental disease leads to disease in those organs, but these studies suggest that infection in the mouth is connected to disease of other organs.

Not only does the chronic infection possibly cause other problems in the body, but as we mentioned earlier, the body's own immune system may be causing detrimental effects to other organs. In humans, one of the inflammatory chemicals, called *C-reactive protein* (C-RP) is thought to be associated with increased risk of heart attacks. Other human studies show elevated levels of C-reactive protein in patients with periodontal disease. There has yet to be a study that says periodontal disease causes heart attacks, mainly because there are so many other variables, such as smoking, high blood pressure, etc, but it certainly deserves consideration. The same should be considered for our pets. While dogs and cats rarely are stricken by a heart attack, we must consider the possibility that the chronic release of the inflammatory chemicals could be contributing to other disease processes.

## Prevention

Our goal is to prevent dental disease before it has a chance to set up a long-term infection. Some things pet owners can do to ward off chronic dental infections are:

- **Brushing the teeth on a daily or every-other-day basis**
- **Examining teeth weekly for:**
  - Fractures
  - Cavity-like lesions
  - Discolorations
  - Inflamed gums

Bring any of these abnormalities to the attention of your veterinarian as soon as possible. Also, one of the most important lines of defense for prevention of long-standing dental disease is the periodic cleaning and dental examination of your pet's teeth by your veterinarian. ■

**HEADS UP:**  
See the important information from your  
veterinarian on the front cover

# February Is National Pet Dental Health Month

According to the American Veterinary Dental Society, 80% of dogs and 70% of cats show signs of oral disease by the time they are 3 years old. Because of the potential health effects, many veterinary hospitals recognize Pet Dental Health Month. Take advantage of this time to focus on your pet's dental health by calling your veterinarian and make an appointment to have your pet's teeth examined and schedule the dental cleaning you might have been putting off. Don't assume that a pet's bad breath is normal—it can be an early sign of gum disease, which can be controlled through regular tooth cleaning. Your pet will thank you with a healthy smile and fresher breath!



## Coming in the Spring issue of Pet Quarterly

New developments in feline heartworm disease

Scabies control for pets

How do dogs and cats learn?

### HEADS UP:

See the important information from your veterinarian on the front cover

**Heartgard<sup>®</sup>**   
*(ivermectin/pyrantel)* **Plus**

### CHEWABLES

**Caution:** Federal (U.S.A.) law restricts this drug to use by or on the order of a licensed veterinarian.

HEARTGARD<sup>®</sup> Plus (ivermectin/pyrantel) Chewables is indicated for use in dogs to prevent canine heartworm disease by eliminating the tissue stage of heartworm larvae (*Dirofilaria immitis*) for a month (30 days) after infection and for the treatment and control of ascarids (*Toxocara canis*, *Toxascaris leonina*) and hookworms (*Ancylostoma caninum*, *Uncinaria stenocephala*, *Ancylostoma braziliense*).

**PRECAUTIONS:** All dogs should be tested for existing heartworm infection before starting treatment with HEARTGARD Plus which is not effective against adult *D. immitis*. Infected dogs must be treated to remove adult heartworms and microfilariae before initiating a program with HEARTGARD Plus.

While some microfilariae may be killed by the ivermectin in HEARTGARD Plus at the recommended dose level, HEARTGARD Plus is not effective for microfilariae clearance. A mild hypersensitivity-type reaction, presumably due to dead or dying microfilariae and particularly involving a transient diarrhea, has been observed in clinical trials with ivermectin alone after treatment of some dogs that have circulating microfilariae.

**Keep this and all drugs out of the reach of children.**

**ADVERSE REACTIONS:** In clinical field trials with HEARTGARD Plus, vomiting or diarrhea within 24 hours of dosing was rarely observed (1.1% of administered doses). The following adverse reactions have been reported following the use of HEARTGARD: Depression/lethargy, vomiting, anorexia, diarrhea, mydriasis, ataxia, staggering, convulsions and hypersalivation.

**SAFETY:** HEARTGARD Plus has been shown to be bioequivalent to HEARTGARD, with respect to the bioavailability of ivermectin. The dose regimens of HEARTGARD Plus and HEARTGARD are the same with regard to ivermectin (6 mcg/kg). Studies with ivermectin indicate that certain dogs of the Collie breed are more sensitive to the effects of ivermectin administered at elevated dose levels (more than 16 times the target use level) than dogs of other breeds. At elevated doses, sensitive dogs showed adverse reactions which included mydriasis, depression, ataxia, tremors, drooling, paresis, recumbency, excitability, stupor, coma and death. HEARTGARD demonstrated no signs of toxicity at 10 times the recommended dose (60 mcg/kg) in sensitive Collies. Results of these trials and bioequivalency studies support the safety of HEARTGARD products in dogs, including Collies, when used as recommended.

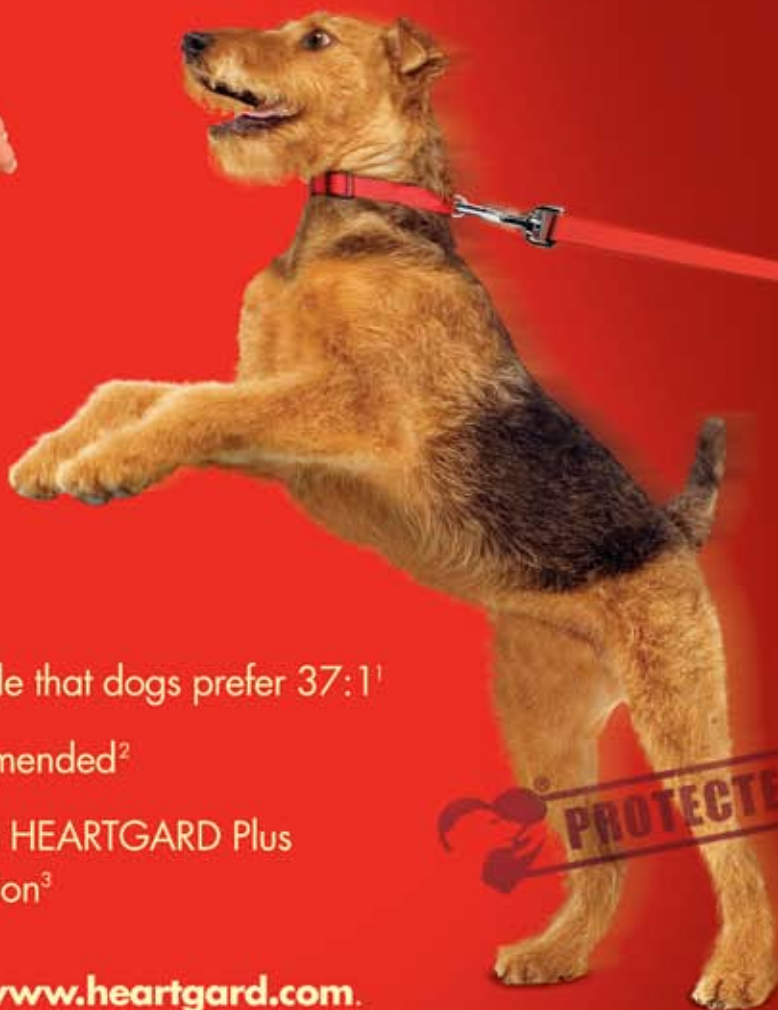HEARTGARD Plus has shown a wide margin of safety at the recommended dose level in dogs, including pregnant or breeding bitches, stud dogs and puppies aged 6 or more weeks. In clinical trials, many commonly used flea collars, dips, shampoos, anthelmintics, antibiotics, vaccines and steroid preparations have been administered with HEARTGARD Plus in a heartworm disease prevention program.

In one trial, where some pups had parvovirus, there was a marginal reduction in efficacy against intestinal nematodes, possibly due to a change in intestinal transit time.



©HEARTGARD is a registered trademark, and <sup>™</sup>the Dog & Hand Logo is a trademark, of Merial.  
©2004 Merial Limited, Duluth, GA. All rights reserved.

# The Real-Beef taste that dogs **can't resist**



- The Real-Beef Chewable that dogs prefer 37:1<sup>1</sup>
- #1 veterinarian-recommended<sup>2</sup>
- Peace of mind with the HEARTGARD Plus Guarantee of Satisfaction<sup>3</sup>



For more information, visit [www.heartgard.com](http://www.heartgard.com).

**Heartgard®**  
(ivermectin/pyrantel)  
Plus  
Easy to give. Protection to live.

<sup>1</sup> Of dogs showing a preference in three studies conducted by independent investigators, dogs preferred HEARTGARD Plus Chewables over INTERCEPTOR® (milbemycin oxime) FLAVOR TABS® by a margin of 37 to 1; data on file at Merial.

<sup>2</sup> Market Dynamics; Monthly share report; Vet dispensed treatments; 4/01/07; data on file.

<sup>3</sup> Guarantee void where prohibited by law. Payment obligation of Merial limited solely to that specified in official Plus Guarantee terms and conditions; any and all other costs expressly excluded.



©HEARTGARD and the Dog and Hand logo are registered trademarks of Merial.  
©INTERCEPTOR is a registered trademark of the Novartis Corporation.  
©FLAVOR TABS is a registered trademark of Novartis AG.  
©2007 Merial Limited, Duluth, GA. All rights reserved. HG007NACONAD.



PRSRT STD  
U.S. POSTAGE  
PAID  
LEBANON  
JUNCTION, KY  
PERMIT NO. 266

# It's Not Just Bad Breath

It May Be Gum Disease

60  
seconds  
once a week  
is all it takes



Good Oral Health Starts with  
Regular Dental Care and OraVet™

Bad breath is often a sign of gum disease – a problem that begins when plaque builds up on your dog's teeth. OraVet fights plaque before it starts, safely and effectively. It's clinically proven and very easy to use. That's why good oral health starts with regular veterinary dental care and OraVet.

Ask your veterinarian about OraVet today!



**OraVet™**

SERIOUS ORAL CARE MADE SIMPLE™

©ORAVET is a registered trademark, and "SERIOUS ORAL CARE MADE SIMPLE" is a service mark, of Merial.  
©2006 Merial Limited, Duluth, GA. All rights reserved.  
DVT-ADS-5-FIRSTLINEAD06.