

PET QUARTERLY

Volume 4, Winter



From your
Veterinarian...



KEEPING YOUR PET'S MOUTH HEALTHY

ADVANCED DENTAL CARE

PERIODONTAL DISEASE:
ANSWERS TO ALL
YOUR QUESTIONS

ORAL TUMORS – DOES
YOUR PET HAVE ONE?

A NEW DENTISTRY
VACCINE

Is your dog trying to tell you something?

FRONTLINE® Plus flea protection lasts longer than the #2 product.

In a head-to-head test, over half the dogs treated with the #2 product had fleas after just one week. The FRONTLINE dogs? Not one flea. FRONTLINE is the one that's waterproof and kills fleas fast all month long. It's the veterinarian's #1 choice.



Say goodbye to fleas and ticks.[™]
www.frontline.com



FRONTLINE is a registered trademark of Merial.
™ Say goodbye to fleas and ticks is a trademark of Merial.
©2005 Merial Limited, Duluth, GA. All rights reserved.



CONTENTS

Beyond Oral Hygiene: Advanced Dental Care / 2

The Dangers of Xylitol / 5

Q&A Periodontal Disease / 6

Oral Tumors: What You Need to Know / 8

Dental Vaccines: A New Preventive Tool / 10

PET QUARTERLY

Pet Quarterly® is an educational resource provided by your veterinary hospital. It is published by Educational Concepts, LLC, Tulsa, Oklahoma.

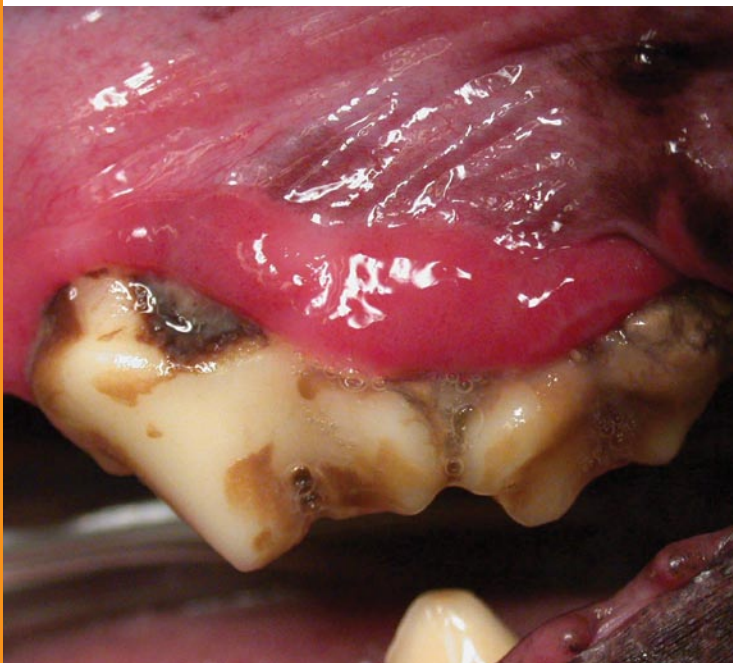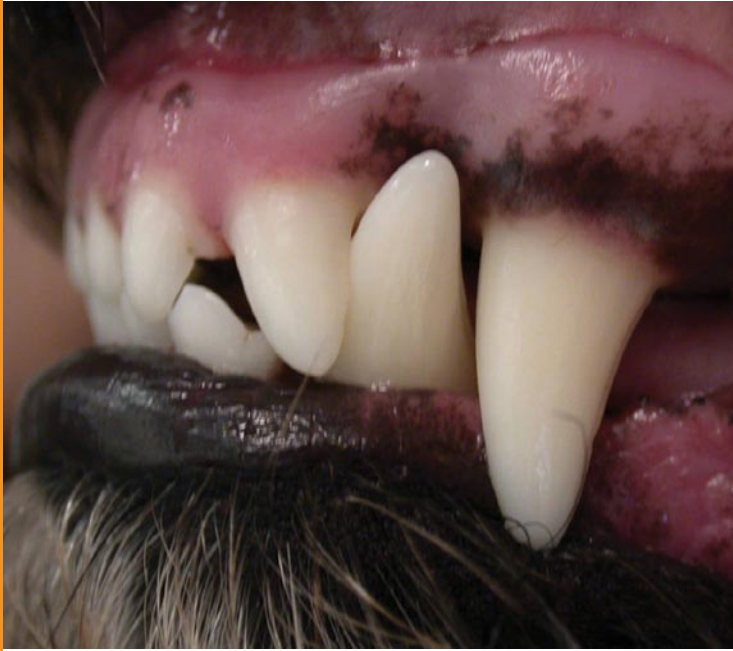Comments are welcome at info@petquarterly.com

©Copyright 2006. All rights reserved. Pet Quarterly® magazine does not make any representations as to opinions or facts as presented. Reproduction of contents in any form is prohibited without prior written permission of the publisher.

BEYOND ORAL HYGIENE

Advanced Dental Care for Your Pet

By Brett Beckman, DVM, FAVD, DAVDC
President-Elect of the American Veterinary Dental College



Top. This pet's teeth are brushed daily to help prevent periodontal disease.

Bottom. This pet has periodontal infection—cleaning alone will not help.

Advances in veterinary dentistry have dramatically changed the way we look at our pets' mouths. Advanced dental training programs for veterinarians and the availability of dental x-rays provide viable options for diagnosing and treating dental conditions.

Unfortunately, pets can't tell us that their teeth or gums hurt. As a result, many cases of oral disease escape detection and pets suffer in silence. Therefore, it is vital for pet owners to seek help from their veterinarian. A complete oral examination including dental x-rays is necessary to discover potentially painful conditions that would otherwise go unnoticed.

More Than Once a Year?

What's that? You have your pet's teeth cleaned every year? Fantastic! However, this is often not enough. As humans, we should brush daily to prevent infection of the gum and bone surrounding the teeth. When we visit our dentists every 6 months they clean and polish our teeth—in other words, our dentists clean teeth that we have already kept reasonably clean. Unfortunately, we can't say that for most of our pets. Limited time and lack of pet cooperation often limit our ability to keep infection (periodontal disease) at bay. Take a moment to smell your pet's breath. If it is offensive, then infection is already present.

Fighting Oral Disease

Advanced training is required to correctly diagnose and treat periodontal infection and

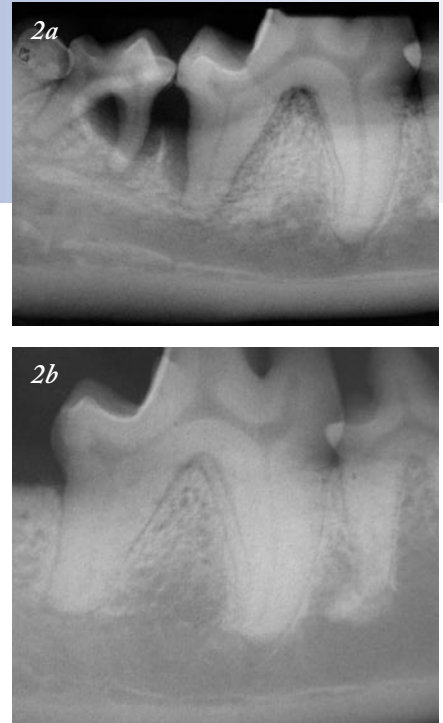
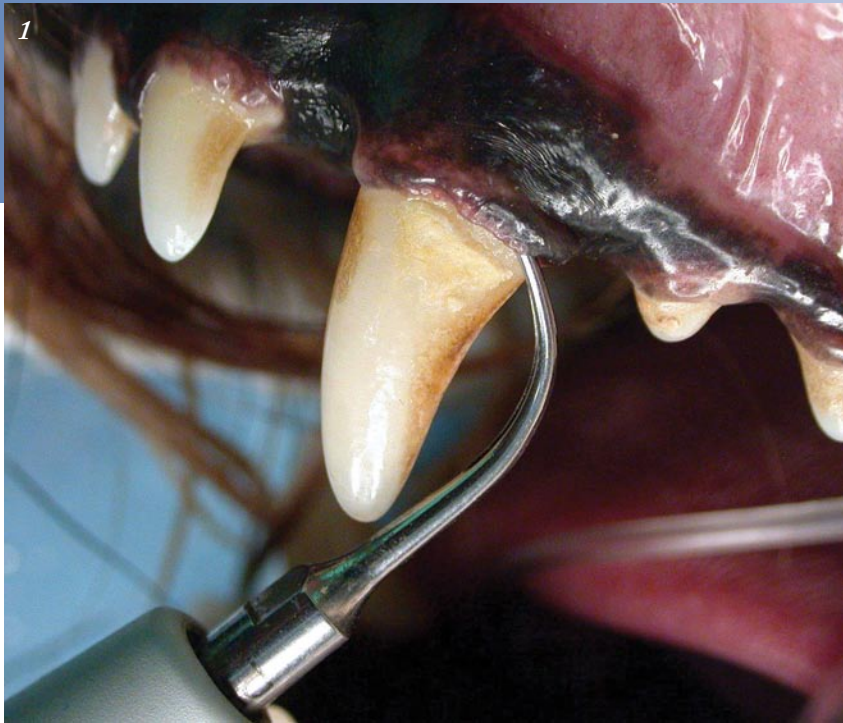

Figure 1. A variety of special instruments is used to clean the tooth root and remove diseased tissue.

Figure 2. An advanced case of periodontal disease. These x-rays show before (a) and 6 months after bone treatment (b).

other conditions such as fractured teeth, discolored teeth, malpositioned teeth, and oral masses (swellings). Many veterinarians have had such training and possess these skills.

It is essential that you see your veterinarian if your pet has a fractured or discolored tooth—your pet may be in severe pain, but showing no sign of it.

Periodontal Disease

Removing root tartar and diseased gum requires special instruments and is often all that is required for very mild periodontal infections (Figure 1). If oral examination shows deeper

infection, an antibiotic gel is often needed as well. If bone is destroyed, gum tissue must often be surgically opened to expose and properly treat the infection. A bone graft is placed at this stage to help grow new bone in the area where it has been lost (Figure 2). If disease has progressed beyond this stage, extraction is often the only viable treatment.

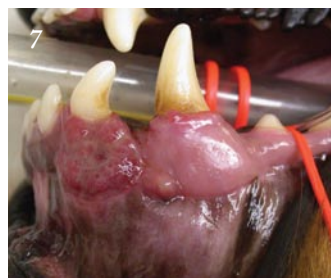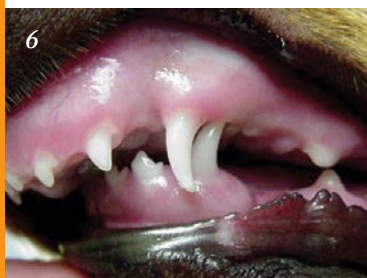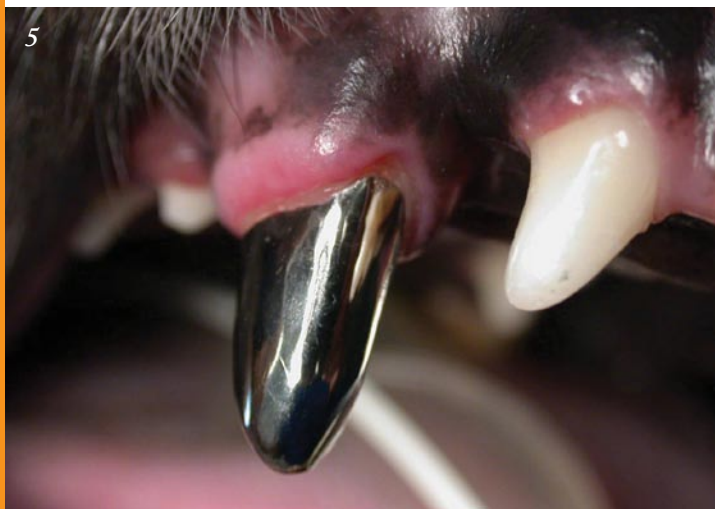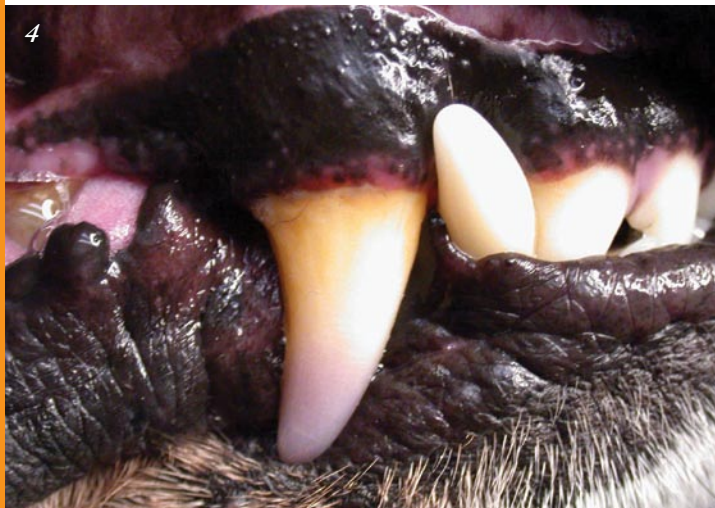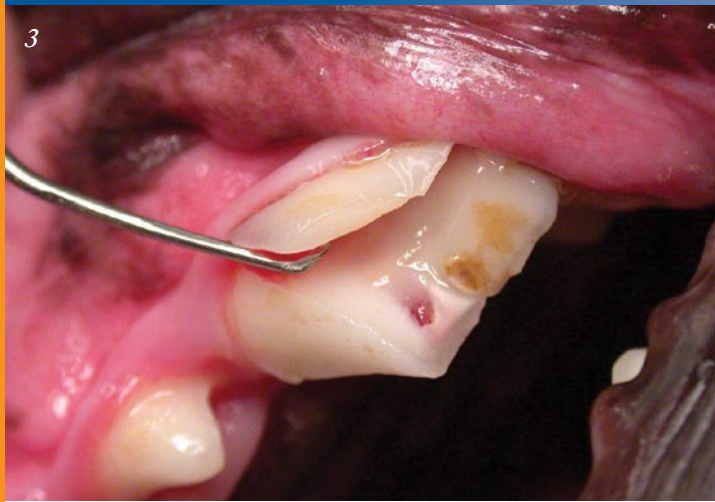Traumatized Teeth

Fractured teeth with exposed pulp require immediate care and are very painful (Figure 3). Tooth fracture results in pulp exposure to oral bacteria. The bacteria then migrate through the root tip to surrounding bone, causing more infection and pain. Ideal treatment involves root canal therapy. Extraction is also an option; however, ignoring the problem is not.

Blunt trauma to a tooth often

causes bleeding into the dentin (material just below the enamel) and tooth discoloration (Figure 4). Recent studies show that a discolored tooth is either already dead or dying. Discolored teeth are treated in the same manner as a fractured tooth with pulp exposure. Root canal therapy or extraction are the only options. Again, doing nothing is not an option! Teeth receiving root canal therapy may require placement of a crown to protect the tooth after treatment (Figure 5). It is essential that you see your veterinarian if your pet has a fractured or discolored tooth—your pet may be in severe pain, but showing no sign of it.

Teeth that cause trauma to other teeth or oral tissue represent a potentially severe problem for pets (Figure 6). Puppies and kittens should be evaluated for malpo-



sitioned teeth, which involve both tooth-on-tooth or tooth-on-tissue problems. Once the adult teeth are in (usually around 6 months of age), have a veterinarian examine your pet's teeth to ensure that no occlusion (the way upper and lower teeth meet when biting down) problems are causing discomfort. Treatment differs according to the specific problem—extraction and orthodontic movement (akin to braces) are among the most common options.

Troublesome Tumors

Oral masses (swellings) often indicate tumors. Both malignant and some benign oral tumors expand to destroy bone and gum tissue (**Figure 7**). Biopsies of oral masses are therefore essential in all cases to allow early detection and prompt treatment. Advances in veterinary dental x-rays allow us to determine the extent of many masses. Other more advanced imaging methods like CT (computed tomography or “CAT” scan) and MRI (magnetic resonance imaging) may need to be used in some cases. Currently, most tumors are curable by surgical removal and new treatment options are being evaluated. (See page 8 for additional information on oral tumors.)

Keep Oral Disease at Bay

Care of pets with oral disease often requires more than teeth cleaning. Please see your veterinarian to determine if your pet has evidence of oral disease. Veterinary dental specialists are available throughout the country to assist your veterinarian in diagnosing oral disease and determining the best treatment plan for your pet. ■

Figure 3. A fractured tooth with exposed pulp that will soon become infected.

Figure 4. Blunt trauma has caused discoloration of this tooth.

Figure 5. A metal crown on this dog's tooth after root canal therapy prevents further wear.

Figure 6. This puppy has an abnormal bite—the lower jaw (mandible) is too short.

Figure 7. Surgical removal of the oral mass shown allowed the patient to recover fully with no tumor regrowth.

Good for You, Not for Fido

XYLITOL POISONING

By Jennifer L. Schori, VMD

Xylitol is a sugar substitute used in sugar-free products such as chewing gum, candy, and baked goods. Xylitol has no known toxic effects in people and has even been promoted as having health benefits. However, the same is not true for your dog. In dogs, xylitol can have serious, sometimes life-threatening, effects. As its use has increased in human products, so have cases of xylitol toxicity in dogs: The Animal Poison Control Center (APCC) of the ASPCA managed more than 170 cases of xylitol poisoning in 2005, up from about 70 cases in 2004. Approximately 114 cases had already been seen by the APCC as of August 2006.

It was initially believed that only large amounts of xylitol would cause toxicity. However, recent reports suggest smaller amounts—as few as 2 sticks of gum in a 20-pound dog—can be harmful. Clinical signs of xylitol poisoning result from a sudden drop in blood sugar and can include depression, loss of coordination, and seizures. There also seems to be a strong link between xylitol consumption and liver failure in dogs. Signs of xylitol toxicity can develop as quickly as 30 minutes after ingestion, or, in the case of smaller ingested amounts, up to 12 hours after ingestion. Research is still pending on the effects of xylitol consumption in other animals.

Products that may contain xylitol:

Gum	Toothpaste
Peppermints & breath mints	Skin care products
Candy	Lipstick
Baked goods	Soap
Diet bars	Vitamins

In the meantime, keep xylitol-containing products out of reach of your pets, and call your veterinarian immediately if you suspect that your pet has consumed something that contains xylitol. ■





PERIODONTAL DISEASE

By Sharon Hoffman,
DVM, DAVDC

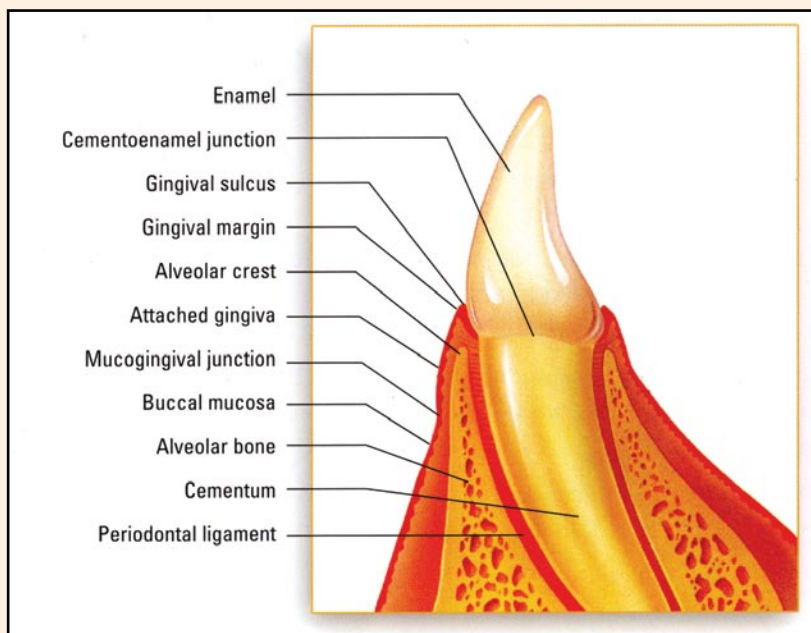
What is periodontal disease?

Periodontal disease is an infection of the periodontium, the area surrounding the tooth. The periodontium consists of four structures: gingiva (gum), alveolar bone (socket where the tooth root is held), cementum (outer lining of root), and the periodontal ligament (ligament that holds the tooth in place).

The disease is caused by bacteria, leading to gingivitis (inflammation of the gums) and often to periodontitis (inflammation of the periodontium). While gingivitis is reversible, periodontitis is not, and it results in pockets of chronic infection around the tooth roots.

Why should I be concerned?

Periodontitis is painful and may lead to premature tooth loss. Severe infections involving the upper teeth in dogs can create a fistula, or opening, between the mouth and sinus cavity, which may cause frequent sneezing. Advanced periodontal disease can also predispose small-breed dogs to fractures of the lower jaw.



Structure of the canine tooth *Courtesy Pfizer*

In the diabetic pet, periodontitis may lead to insulin resistance and poor control of blood sugar. There is also a relationship between the severity of periodontal disease and inflammation of the liver, kidneys, lungs, and heart.

Are there any breeds predisposed to periodontal disease?

Small-breed dogs are frequently affected by periodontal disease—it is not uncommon to find periodontitis in dogs 2 years of age, and advanced periodontitis and tooth loss by the age of 4. Greyhounds are a larger breed commonly affected with periodontal disease.

How do I know if my pet is suffering from periodontal disease?

Periodontal disease hides under the lips and gums, and unfortunately, your pet can't tell you when he or she is in pain. You may notice a foul odor from your pet's mouth, but because the disease comes on gradually, you may miss it. Your pet may avoid chewing hard food or its favorite chew toys. Cats

may swallow hard food without chewing. The best way to detect periodontal infection in your pet is to have an oral examination performed by your veterinarian.

How will my veterinarian detect periodontal disease?

Since three of the four areas infected by periodontal disease are under the gum, your veterinarian will need to use a special instrument, a periodontal probe, to detect "pockets" around each tooth. When a pocket is detected, it is recorded on a dental chart, and your veterinarian will take a radiograph to diagnose the extent of the destruction around the tooth. This is exactly the same process your dentist uses to detect periodontal disease in your mouth; however, veterinary patients require general anesthesia.

Why shouldn't I have "anesthesia-free dentistry" performed?

More and more pet care providers are advertising "anesthesia-free dentistry." Calculus, or tartar, accumulates on the crowns of the teeth

and is often brown and unsightly. It is the calculus that is partially removed during “anesthesia-free dentistry.” This technique neither prevents nor treats periodontal disease. Rather, it is a cosmetic procedure. Remember, periodontal disease occurs below the gum around the roots of the teeth. It is *impossible* to treat these areas in pets without general anesthesia. With “anesthesia-free dentistry,” the infection and disease remain hidden below the gum and pain and destruction will continue. In addition, the instruments used to remove calculus are sharp. Any unexpected movement, which can be expected from pets in pain from periodontal disease, could cause injury to the pet’s gum, lips, tongue, or eyes.

What is the difference between a dental “prophy” and periodontal treatment?

Dental prophylaxis, often referred to as a “prophy,” is cleaning and polishing of the teeth (above and below the gum) for *prevention* of periodontal disease. Once periodontal disease has begun to destroy the areas around the tooth roots, the patient needs periodontal *treatment*.

The goal of treatment is to relieve pain and control periodontitis and it involves not only cleaning and polishing the crowns (enamel) of the teeth, but also cleaning the pockets and tooth roots. It may also include applying an antibiotic under the gum or periodontal (gum and bone) surgery. A temporary plaque barrier (Oravet®) may be applied to the crowns of the teeth to prevent plaque (which harbors bacteria) from adhering.

Because periodontitis can only be controlled, not cured, treatment must be done more often (two to four times per year) than prophylaxis.

It also costs more than a basic cleaning.

Can cleaning be done with sedation instead of anesthesia?

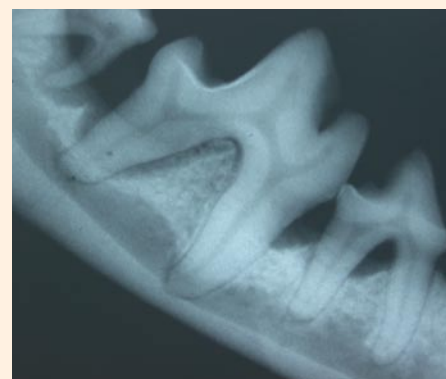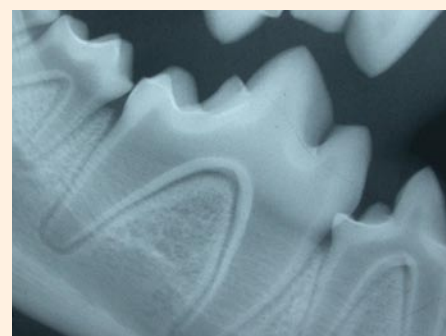
Sedation for a dental cleaning is risky. It doesn’t allow for respiratory support and doesn’t prevent water, saliva, or calculus from entering the lungs. In many cases, it doesn’t allow intraoral radiographs to be taken. Sedation is also time-limiting—the procedure has to be stopped when the sedation wears off, even if there is more cleaning to be done.

What can be done to decrease the risks of anesthesia for my senior pet?

Treatment of dental disease in the senior patient invariably leads to improved quality of life. However, pet owners’ fear of anesthesia is one of the biggest deterrents to professional pet dental care.

Certain procedures can decrease the risks of anesthesia in patients, especially senior pets who may have preexisting medical illnesses. A general physical examination and blood and urine tests should be done in all patients. Your veterinarian may also recommend an ECG, chest radiographs, or an echocardiogram based on your pet’s individual needs. These tests give your veterinarian information about your pet’s preexisting risk factors, medications to use or avoid, and how to prepare your pet for the procedure.

During anesthesia, the pet’s vital signs will be monitored continuously to prevent and detect any complications. Pain medication will be provided before, during, and after the procedure to help improve recovery from anesthesia. These procedures add expense but are essential in decreasing risk factors.



Top. X-ray of normal teeth
Bottom. X-ray of teeth with periodontal disease

Can periodontal disease be treated with antibiotics?

Plaque bacteria are much more resistant to antibiotics than the bacteria that cause most infections. Antibiotics without periodontal treatment are ineffective in managing and controlling periodontitis.

What can I do for my pet with periodontal disease?

Following professional periodontal treatment, your veterinarian will recommend daily dental home care for your pet. The care you provide at home between professional treatments is essential in controlling periodontal disease and providing continued comfort for your pet. In addition, a new vaccine is available that can help prevent periodontitis in healthy pets (see article on page 10). ■

ORAL TUMORS

By Jan Bellows, DVM, DAVDC and DABVP (Canine and Feline)

Just like other parts of a dog or cat's body, the mouth can develop growths. They may be caused by infection of the gum or problems with a tooth or teeth or they can be tumors. The mouth is a common site for a variety of tumors and certain breeds are more likely to have these tumors than others. For example, black cocker spaniels are prone to oral melanomas, while boxers are prone to mast cell tumors.

Tumors of the mouth can be benign or malignant. Benign tumors may spread to nearby tissues, but malignant tumors have the ability to spread to distant organs (a process known as metastasis).

Benign Tumors

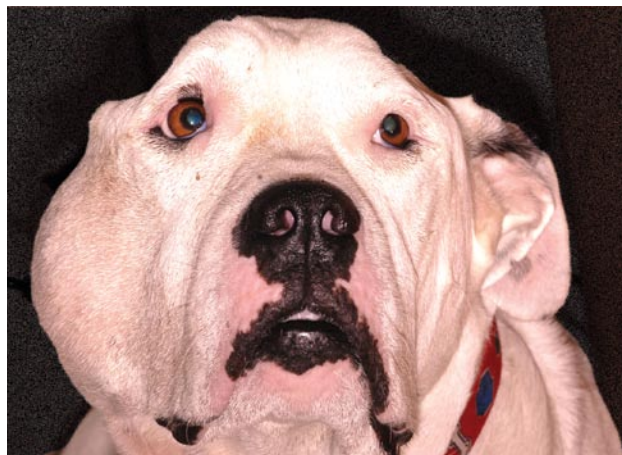
The most common type of benign oral tumor is the *epulis*. These tumors usually arise from the periodontal ligament of the tooth (see illustration of the tooth's anatomy, page 6) and can affect dogs and cats of all ages. Epulides usually have a smooth, pink surface and require surgical removal of both the tumor and surrounding tissues, including the tooth.

One type of epulis, known as an acanthomatous epulis, is classified as benign but tends to invade adjacent bone. To treat these tumors, the tumor as well as surrounding tissue and diseased bone, if any, must be removed. Surgery may be combined with radiation therapy.

Malignant Tumors

Malignant melanoma is the most common malignant oral tumor in dogs. These tumors are most common in male dogs, especially cocker spaniels, German shepherds, chow chows, and dogs with heavily pigmented mucous membranes (gums). They are aggressive and often spread to the lymph nodes and lungs by the time they are diagnosed. Treatment can include surgery, radiation therapy, and/or injection of chemotherapeutic drugs into the tumor itself.

Squamous cell carcinoma (SCC) is the second most common malignant tumor in dogs and the most common type in cats. In dogs, older, larger breeds are more likely to



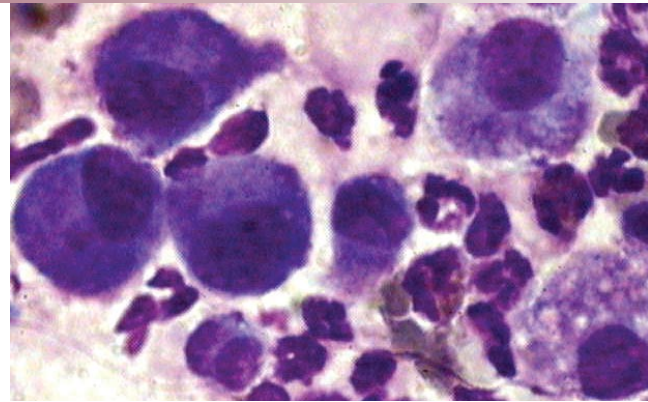
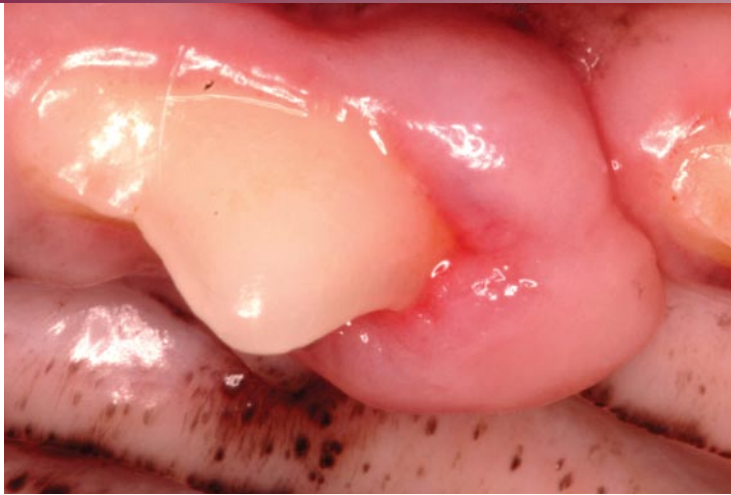Swelling due to a malignant oral tumor

have these tumors. They arise from the gums and are red and ulcerated, sometimes with cauliflower-like projections. SCC may invade local tissue and spread to other areas. Treatment can include surgery, radiation, and/or chemotherapy.

Did You Know?

February is National Pet Dental Health Month.

According to the American Veterinary Dental Society, 80% of dogs and 70% of cats show signs of oral disease by the time they are 3 years old. Because of the potential health effects to pets, many veterinary hospitals recognize Pet Dental Health Month and are happy to provide information to clients who want to do the best for their pets. Take advantage of this time to focus on your pet's dental health: call ahead to make an appointment for your veterinarian to check your pet's teeth, schedule the dental cleaning you might have been putting off, or find out how you can help keep your pet's teeth healthy at home year-round. Your pet will thank you with a healthy smile and fresher breath!



Left. Benign epulis oral tumor

Right. Abnormal cells from an oral tumor.

Fibrosarcomas are another type of malignant tumor that can occur in the mouth. In dogs, these tumors tend to arise most commonly from the maxilla (the upper half of the mouth) of large, male, middle-aged animals, especially retrievers. In cats, they are locally invasive and unlikely to spread. Treatment includes surgically removing the tumor and some surrounding tissue and/or radiation therapy.

How Are Oral Tumors Diagnosed?

Your veterinarian is your pet's greatest ally in diagnosing oral tumors. Often, a tumor will not be noticed until an oral examination is performed at your veterinary clinic. Most pets will not show signs of oral tumors until the mass becomes large enough to inhibit chewing or swallowing. Some pets with oral tumors have bad breath, excessive drooling, and/or a bloody oral discharge. Other animals will develop a swelling on the outside of the oral cavity. Because of this, regular visual examination of your

pet's mouth, both at home and at your veterinary clinic, is important.

Once you or your veterinarian notices an oral mass, tests must be performed to determine the cause of the swelling and to plan appropriate care. Your veterinarian may take a sample of cells from the mass and examine it under a microscope, or a larger tissue specimen may be removed for testing to determine whether the cause is infection or a tumor. Blood tests and chest x-rays may also be performed to evaluate your pet for metastasis if a tumor is diagnosed or suspected.

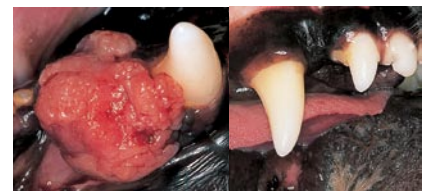What Is the Prognosis for Oral Masses?

The prognosis is directly related to the type of mass, where it is located, and how it is treated. With therapy, dogs and cats affected with benign tumors usually have a normal life span. Animals with aggressive malignant tumors, however, often live for only weeks to months after diagnosis, with or without treatment.

As in humans, early diagnosis is critical to long-term survival. See your veterinarian for an examination at least twice yearly and get used to looking into your dog or cat's mouth frequently for abnormalities. Your best friend will thank you. ■

Left. Malignant squamous cell carcinoma oral tumor

Right. Healed lower jaw after successful tumor removal.



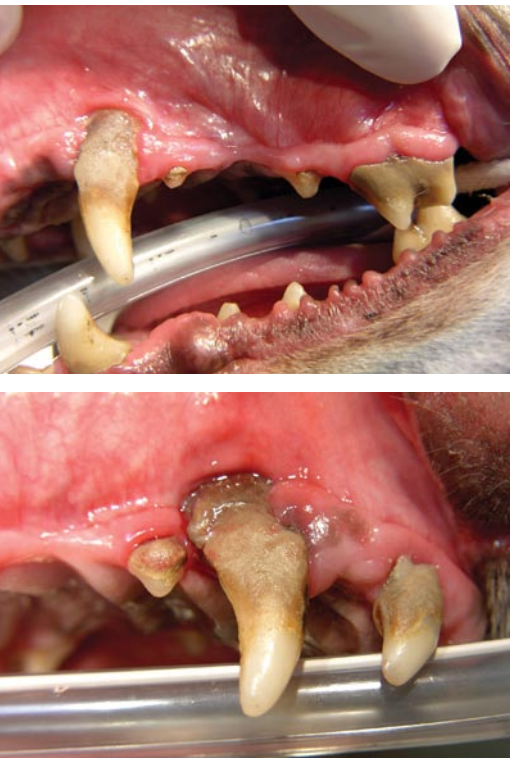Symptoms of Oral Tumors

- Bad breath
- Excessive drooling
- Bloody oral discharge
- Swelling on outside of oral cavity

DENTAL VACCINES

A New Method for Managing the Most Common Disease in Pets

By R. Michael Peak, DVM, DAVDC



This mouth is in need of dental care—note the plaque and tartar accumulation, gum recession and inflammation, and missing teeth.

Symptoms of Periodontal Disease

- Plaque & tartar accumulation
- Gum recession
- Gingivitis (inflammation of the gum)
- Missing teeth
- Root exposure
- Pus at the gum line
- Halitosis (bad breath)

Do you know what the most common disease in dogs and cats is? According to a study conducted at the University of Minnesota, as well as mounting supporting evidence, periodontal disease is the most common disease our pets have.¹

Periodontal disease is inflammation or infection of the tissues that surround and support the teeth. It occurs for a number of reasons, but the primary causes are bacterial growth in the mouth and lack of regular oral hygiene. Other influencing factors include genetic predispositions, pH of the oral cavity, nutritional status, the consistency of food eaten, and stress (yes, even though they may not show it, our pets often have stress). More recently, researchers have found that the type of bacteria may play a more important role than once thought.²

What Research Has Shown

It has been known for many years in human dentistry that periodontal disease goes hand in hand with other diseases and conditions such as diabetes, preterm low birth weight babies, and the incidence of cardiovascular disease (stroke).³⁻⁸ Early in periodontal research, it was assumed that as plaque (which harbors bacteria) developed, more advanced disease followed. However, we know now that this is not always the case.

Some people have much worse periodontal disease than would be

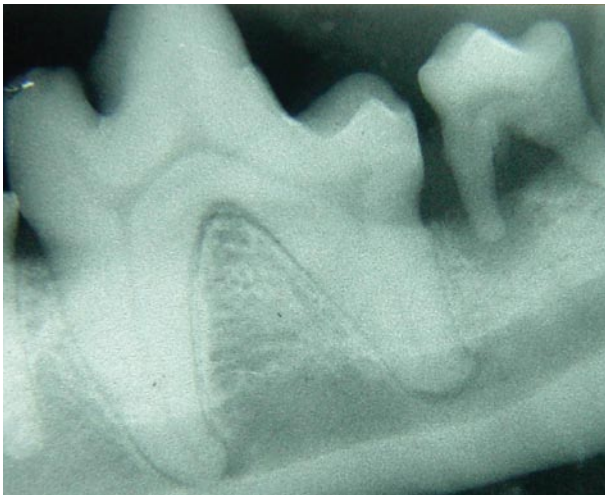
expected considering the level of plaque, calculus (tartar), and overall oral hygiene. You may have noticed the same thing in your pets—some seem to have more severe signs of dental disease than others. Many human and veterinary studies are now focusing on particular bacteria and its effect on the development of advanced periodontal disease.

The ultimate result of periodontal disease is loss of bone around the tooth roots and eventual loss of the tooth.

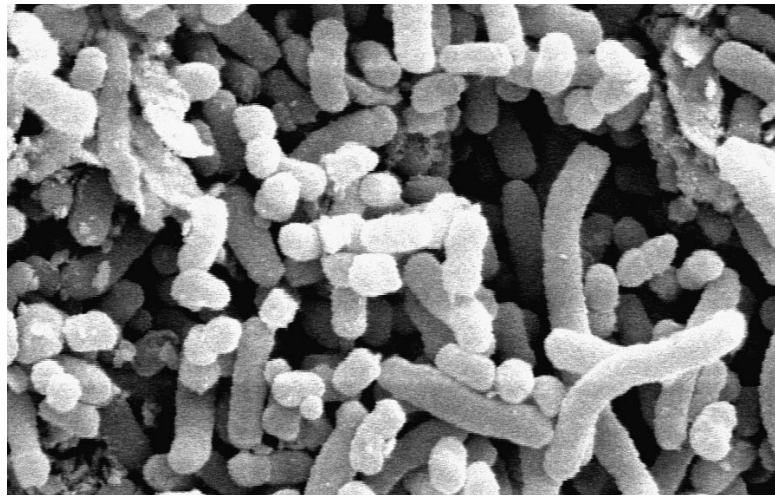
Near & Far Consequences

Locally, periodontal infections eat away at the gingival attachment (tooth/gum attachment), the bone around the tooth roots, and the ligament that holds the tooth root to the bone. The ultimate result is loss of bone around the tooth roots and eventual loss of the tooth. While this may seem bad, it is only the beginning of the story.

Loss of bone around the root may have a dramatic impact on the overall stability and integrity of the jaws, and in some cases



Left. Dental x-rays are important to evaluate the full extent of periodontal disease. In this case, the tooth on the right has extensive bone loss around both roots (arrows).



Right. *Porphyromonas* bacteria Courtesy Pfizer

Studies in the United States and in Europe have now shown associations between periodontal disease and changes in the heart, liver, and kidneys in dogs.

results in such weakening of the lower jaw that jaw fracture follows. These “pathologic” fractures of the lower jaw are difficult to treat because of bone infection and the small amount of healthy bone left for healing. The other effect of periodontal disease is the constant immune response and release of toxic by-products from the bacteria within the periodontal tissues.

Periodontal infection can also have far-reaching effects throughout the body. Studies in the United States and in Europe have now shown associations between periodontal disease and changes in the heart, liver, and kidneys in dogs.⁹

The Culprit: *Porphyromonas*

In humans, a bacteria called *Porphyromonas gingivalis* has been identified as being associated with periodontal infection and advanced periodontal tissue loss. In dogs, the

bacteria *Porphyromonas* is slightly different in its make-up. In fact, researchers have found that there are three *Porphyromonas*-type bacteria associated with greater than 75% of cases of advanced periodontal disease in dogs.² It is proposed that control of these bacteria may result in less periodontal tissue loss, less tooth loss, less loss of important jaw structure, and less damage to the overall body.

One way to control these bacteria would be to stimulate the body to create an immune response that would target these bacteria specifically. A vaccination that is aimed at the *Porphyromonas* bacteria responsible for most periodontal tissue infections has been developed.¹⁰ Safety studies and several studies to see how well the vaccines work have been completed. The results are promising and this vaccine is now available in veterinary clinics for administration to patients.

<<Author:
Okay as
edited?>>

The vaccine has only been studied in dogs, but a feline periodontal disease vaccine may be available in the future.

Vaccine Candidates

Studies have shown that smaller dogs and older dogs are more likely to be affected with advanced periodontal disease. Also any dog with a familial tendency toward periodontal disease as well as larger breeds that are predisposed, such as greyhounds, would be good candidates for this type of protection. As with any immunization, any information you can provide about your pet’s history will help your veterinarian assess your pet’s risk for disease, need for protection, and the appropriateness of the vaccine.

Any dog with a familial tendency toward periodontal disease as well as larger breeds that are predisposed, such as greyhounds, would be good candidates for this type of protection.

Prevention: Multi-Faceted

The obvious question becomes, if we do away with these bacteria, won't other bacteria just come in and take their place? The answer is yes; however, if the new colonizing bacteria are not pathogenic or destructive in nature, then we shouldn't see the undesirable effects.

This brings up an important point about these bacteria—managing them will not prevent plaque from building up on the surface of the tooth or circumvent the need for home care, routine professional dental cleaning, and oral examination by your veterinarian. Preventing and managing bacteria in conjunction with regular dental care from your veterinarian will result in a healthier mouth and happier pet. ■

References

1. **Health status and population characteristics of dogs and cats examined at private veterinary practices in the United States.** Lund EM, Armstrong PJ, Kirk CA, et al. *JAVMA* 214:1336-1341, 1999.
2. **Pigmented-anaerobic bacteria associated with canine periodontitis.** Hardham J, Dreier K, Wong J, et al. *Vet Microbiol* 106:119-128, 2005.
3. **Systemic effects of periodontal diseases.** Scannapieco FA. *Dent Clin North Am* 49:533-550, 2005.
4. **Potential role of microorganisms isolated from periodontal lesions in the pathogenesis of inflammatory bowel disease.** Van Dyke TE, Dowell DR, Offenbacher S, et al. *Infect Immun* 53:671-677, 1986.
5. **Periodontal disease and cardiovascular disease, epidemiology and possible mechanisms.** Genco R, Offenbacher S. *JADA* 133:14s-22s, 2002.
6. **The periodontal infection-systemic disease link: A review of the truth or myth.** Paquette DW. *J Intl Acad Periodontol* 4:101-109, 2002.
7. **Relationship of periodontal disease and edentulism to stroke/TIA.** Elter JR, Offenbacher S. *J Dent Res* 82:998-1001, 2003.
8. **Relationship between periodontal disease and C-reactive protein among adults in the Atherosclerosis Risk in Communities study.** Slade GD, Ghezzi EM, Heiss G, et al. *Arch Intern Med* 163:1172-1179, 2003.
9. **Effects of dental disease on systemic health.** DeBowes LJ. *Vet Clin North Am Small Anim Pract* 28:1057-1062, 1998.
10. **Evaluation of a monovalent companion animal periodontal disease vaccine in an experimental mouse periodontitis model.** Hardham J, Reed M, Wong J, et al. *Vaccine* 23:3148-3156, 2005.

Is Your Pet at Risk?

American Kennel Club registration figures for 2005 show that of the 20 most popular dog breeds, 10 are small breeds: Yorkshire terriers, dachshunds, poodles, Shih Tzus, miniature schnauzers, Chihuahuas, pugs, pomeranians, Boston terriers, and Malteses.

Small breed dogs are at greater risk for periodontal disease because their teeth are often crowded together resulting in an increased accumulation of plaque. However, some large breed dogs such as greyhounds are predisposed as well—you can prevent and manage periodontal disease in your pet with regular veterinary dental visits.

Heartgard®
(ivermectin/pyrantel) **Plus**

CHEWABLES

Caution: Federal (U.S.A.) law restricts this drug to use by or on the order of a licensed veterinarian.

HEARTGARD® Plus (ivermectin/pyrantel) Chewables is indicated for use in dogs to prevent canine heartworm disease by eliminating the tissue stage of heartworm larvae (*Dirofilaria immitis*) for a month (30 days) after infection and for the treatment and control of ascarids (*Toxocara canis*, *Toxascaris leonina*) and hookworms (*Ancylostoma caninum*, *Uncinaria stenocephala*, *Ancylostoma braziliense*).

PRECAUTIONS: All dogs should be tested for existing heartworm infection before starting treatment with HEARTGARD Plus which is not effective against adult *D. immitis*. Infected dogs must be treated to remove adult heartworms and microfilariae before initiating a program with HEARTGARD Plus.

While some microfilariae may be killed by the ivermectin in HEARTGARD Plus at the recommended dose level, HEARTGARD Plus is not effective for microfilariae clearance. A mild hypersensitivity-type reaction, presumably due to dead or dying microfilariae and particularly involving a transient diarrhea, has been observed in clinical trials with ivermectin alone after treatment of some dogs that have circulating microfilariae.

Keep this and all drugs out of the reach of children.

ADVERSE REACTIONS: In clinical field trials with HEARTGARD Plus, vomiting or diarrhea within 24 hours of dosing was rarely observed (1.1% of administered doses). The following adverse reactions have been reported following the use of HEARTGARD: Depression/lethargy, vomiting, anorexia, diarrhea, mydriasis, ataxia, staggering, convulsions and hypersalivation.

SAFETY: HEARTGARD Plus has been shown to be bioequivalent to HEARTGARD, with respect to the bioavailability of ivermectin. The dose regimens of HEARTGARD Plus and HEARTGARD are the same with regard to ivermectin (6 mcg/kg). Studies with ivermectin indicate that certain dogs of the Collie breed are more sensitive to the effects of ivermectin administered at elevated dose levels (more than 16 times the target use level) than dogs of other breeds. At elevated doses, sensitive dogs showed adverse reactions which included mydriasis, depression, ataxia, tremors, drooling, paresis, recumbency, excitability, stupor, coma and death. HEARTGARD demonstrated no signs of toxicity at 10 times the recommended dose (60 mcg/kg) in sensitive Collies. Results of these trials and bioequivalency studies support the safety of HEARTGARD products in dogs, including Collies, when used as recommended.

HEARTGARD Plus has shown a wide margin of safety at the recommended dose level in dogs, including pregnant or breeding bitches, stud dogs and puppies aged 6 or more weeks. In clinical trials, many commonly used flea collars, dips, shampoos, anthelmintics, antibiotics, vaccines and steroid preparations have been administered with HEARTGARD Plus in a heartworm disease prevention program.

In one trial, where some pups had parvovirus, there was a marginal reduction in efficacy against intestinal nematodes, possibly due to a change in intestinal transit time.



©HEARTGARD is a registered trademark, and ™the Dog & Hand Logo is a trademark, of Merial.
©2004 Merial Limited, Duluth, GA. All rights reserved.

He's either begging for steak, or **Heartgard[®] Plus** (ivermectin/pyrantel)



Ask your Vet about HEARTGARD[®] Plus, the Real-Beef Chewable that offers safe, proven prevention against deadly heartworm disease, plus treatment and control of hookworms and roundworms that may be spread to your family.

Help keep your pet safe in a scary world with HEARTGARD[®] Plus.

Heartgard[®] Plus
(ivermectin/pyrantel)

More Vets choose it.
More pets chew it.

Visit www.heartgard.com to learn more about HEARTGARD Plus and to sign up for monthly e-mail reminders.



HEARTGARD is a registered trademark, and "The Dog & Hand Logo" is a trademark, of Merial. ©2005 Merial Limited, Duluth, GA



HEARTGARD is well-tolerated. All dogs should be tested for heartworm infection before starting a preventive program. Following the use of HEARTGARD, digestive and neurological side effects have been reported. For more information contact your veterinarian.

PRSRT STD
U.S. POSTAGE
PAID
LEBANON
JUNCTION, KY
PERMIT NO. 266

It's Not Just Bad Breath

It May Be Gum Disease

60
seconds
once a week
is all it takes



Good Oral Health Starts with
Regular Dental Care and OraVet™

Bad breath is often a sign of gum disease – a problem that begins when plaque builds up on your dog's teeth. OraVet fights plaque before it starts, safely and effectively. It's clinically proven and very easy to use. That's why good oral health starts with regular veterinary dental care and OraVet.

Ask your veterinarian about OraVet today!

 **OraVet™**
SERIOUS ORAL CARE MADE SIMPLE™

©ORAVET is a registered trademark, and "SERIOUS ORAL CARE MADE SIMPLE" is a service mark, of Merial.
©2006 Merial Limited, Duluth, GA. All rights reserved.
OVT-ADS-5-FIRSTLINEAD06.